

# INNOVATIVE IMPLANT SOLUTIONS

*"This long-term male patient had increasing concerns about his overall appearance. As a Professional Engineer who owned and managed his own firm, he was constantly in the public eye, both in terms of his networking and his "sales" activities. As such, his deteriorating oral health was impacting not only on his smile but actually aging him perceptibly as time went on.*

*Yet, as a busy entrepreneur, he had always also felt he could not afford the time required for a comprehensive solution. This had resulted in a series of "quick fixes" to a series of dental complaints including extractions, bridgework, crowns and other restorations – as his overall dental health continued to decline. In the past, he had suffered from headaches while his current situation was a litany of broken teeth and rampant decay. Finally, at one visit, I outlined two different overall approaches for him. The first was the placement of crowns, bridges and cast partials, which would resolve his functional issues but would not deliver the overall esthetic results he desired. The second was the concept of a "non-surgical facelift" through Full Mouth Reconstruction, improving his overall appearance and well being by correcting his vertical, his bite and creating a more comfortable jaw position. He finally decided that it was time to face his concerns head on and he selected the second option.*

*We began by determining his comfortable jaw position. At the same time, we utilized Diagnostic software, in conjunction with the Aurum Ceramic/Classic Implant Team, to determine the optimal placement for a number of implants as the foundation for a new fixed bridge (#2-4 - #2-6) and single crowns on #1-6, #1-7*

*and #3-6. After implant placement (by Dr. Cliff J. Revell) and healing, Fixed Lower and Upper Orthotics were placed to correct his jaw alignment and calibrate his proper vertical positioning. These remained in place for six months. The K-7 was then employed to confirm we had indeed created an accurate bite.*

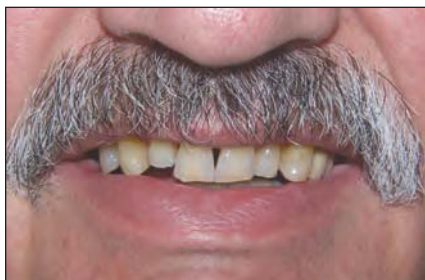*Aurum Ceramic/Classic created a Diagnostic Wax-up as per their ACCES™ system, which the patient enthusiastically accepted. His remaining dentition was prepared and temporized following the LVI protocol for esthetic reconstruction with the Aurum Ceramic/Classic Advanced Esthetic (AE) Team providing Prep Indices, Bite Stent and Siltec Provisional Stent. The implant-based restorations were created utilizing Zirconia-based Contessa™ with IPS Empress (Shade 020) crowns employed to restore the remaining dentition, all beautifully crafted by Aurum Ceramic/Classic.*

*This case has now been in place for one year with excellent results in all aspects of the bite and esthetics. The patient is extremely pleased (as you can see in the After Full Face photo) with his "non-surgical facelift" and definitely looks and feels happier and healthier. As he puts it, "People are always complimenting me on my smile. They ask which toothpaste I use to keep my teeth so bright. No one seems to realize that these aren't my natural teeth." And, that's what makes it all worthwhile in my opinion."*

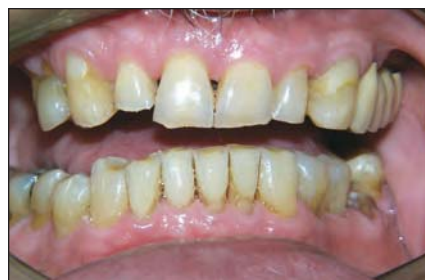*Dr. Alex Pavlenko*



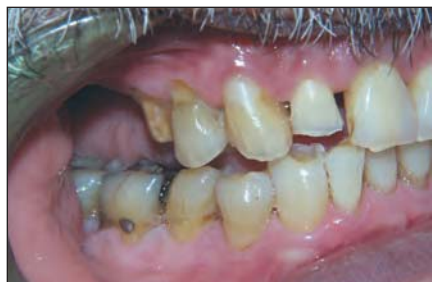Full Face Before.



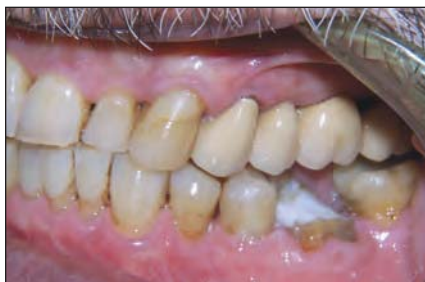Smile Before.



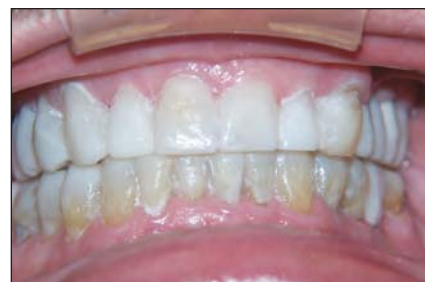Retracted Smile Before.



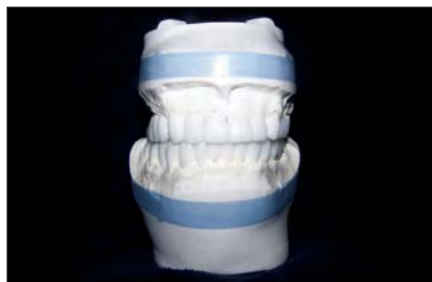Right Side Before.



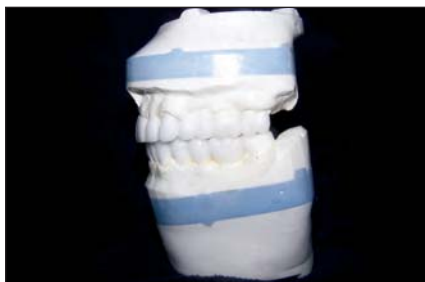Left Side Before.



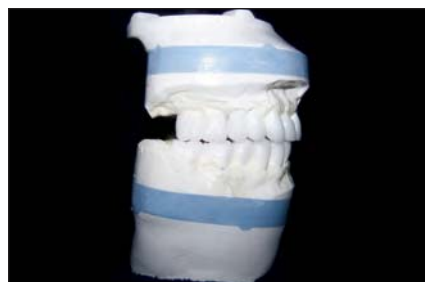Fixed Orthotic.



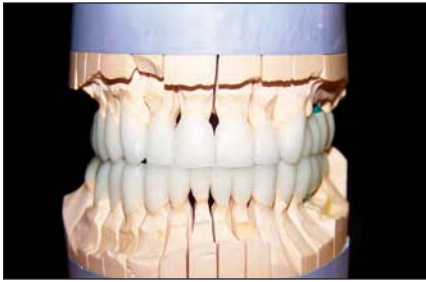Preoperative Waxup - Front View.



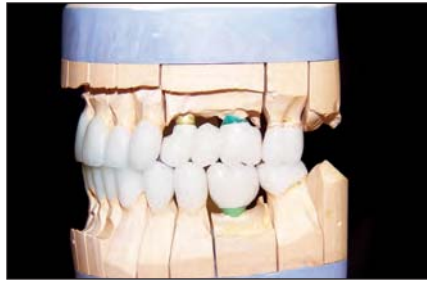Preoperative Waxup - Left View.



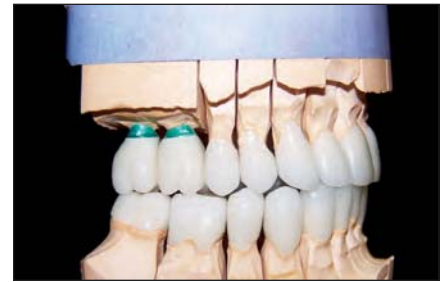
Preoperative Waxup - Right View.



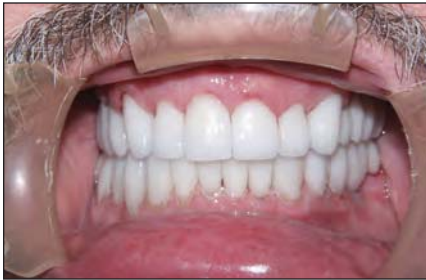*IPS Empress - Model Front.*



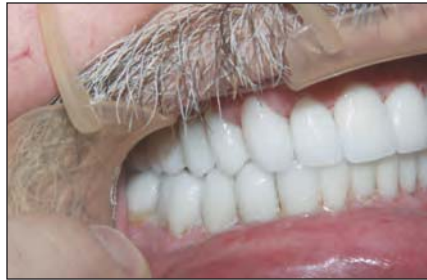*IPS Empress - Model Left.*



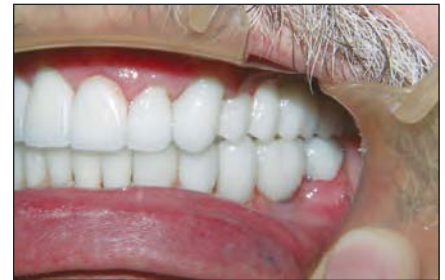*IPS Empress - Model Right.*



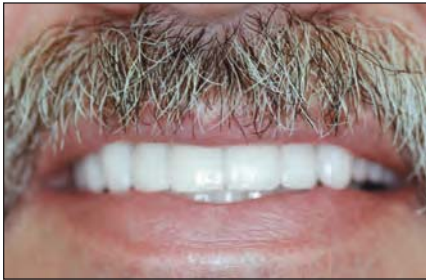*Retracted Smile After Seating.*



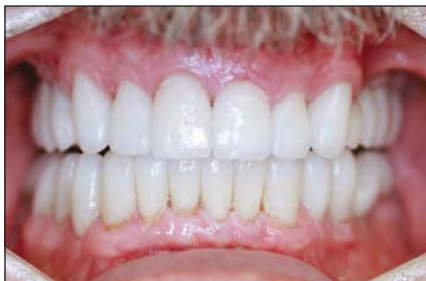*Right Side After Seating.*



*Left Side After Seating.*



*Smile After*



*Retracted Smile After.*



*Full Face After.*

A graduate of Poltava Dental Medical Stomatological Academy in the Ukraine in 1984, Dr. Alex Pavlenko emigrated to Canada in 1998, bringing his family with him. He spent the first two and a half years in the University Coordinating Council of the University of Alberta qualification program, writing and passing his exams in 2001, which granted him his Canadian Dental license. Dr. Pavlenko set up his general practice in Edmonton at that point where he continues today with an emphasis on Neuromuscular and Cosmetic Dentistry. Dr. Pavlenko and his team are active and enthusiastic participants in Continuing Education. He is a member of IACA, CDA, the Alberta Dental Association and the Edmonton District Dental Society.